

## ACHIEVING THE EPITOME OF COMPOSITE ART: CREATING NATURAL TOOTH ESTHETICS, TEXTURE, AND ANATOMY USING APPROPRIATE PREPARATION AND LAYERING TECHNIQUES



by  
Brian LeSage, DDS, FAACD  
Beverly Hills, CA  
www.cosmetic-dentistry.com

Frank Milnar, DDS  
St. Paul, MN  
www.milnardds.com

Jenifer Wohlberg  
Stillwater, MN  
jenny@valleydentalarts.com

### ABSTRACT

This article will be valuable to Accreditation Case Type V (Six or More Direct Resin Veneers) candidates by facilitating understanding of the layering techniques required to produce natural esthetics and accurately create natural-looking texture and anatomy in direct resin restorations. By engaging the reader in a total esthetic concept—one that progresses from the micro, minute portions of the tooth (eg, different thicknesses of enamel, translucency, and surface texture) into the macro (eg, smile line, midline, and axial inclinations)—realism can be imparted to a Case Type V so that an ultimately better-looking smile can be achieved. Additionally, this article reviews concepts for pre-planning the restorative process, utilizing an esthetically enhanced study model, and incorporating a putty matrix into the clinical protocol.

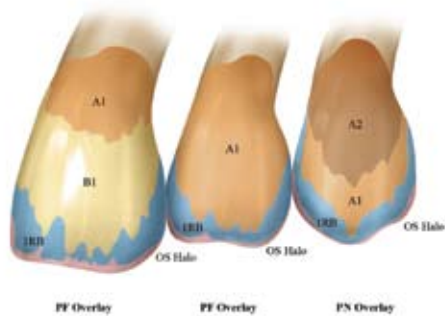
---

*Three-dimensional restorations with realistic depth of color can be achieved only by combining anatomically correct form with creative use of the artist's palette.*

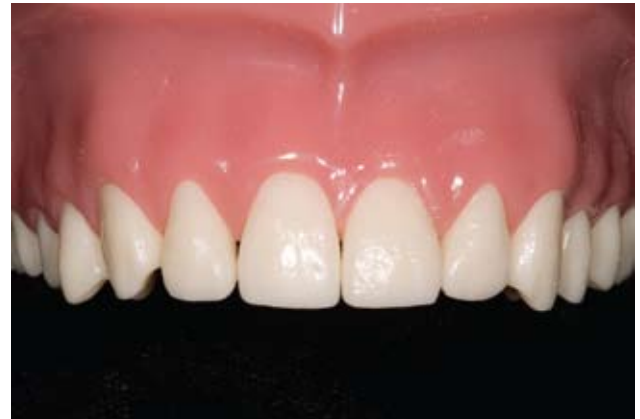---

### INTRODUCTION

Three-dimensional restorations with realistic depth of color can be achieved only by combining anatomically correct form with creative use of the artist's palette. Morphologically correct composite restorations are built up according to a logical method of carefully selected composite shades, tints, and opaques that incorporate differing optical properties. When properly combined, they create the illusion of the different translucencies and opacities that are visible in natural tooth structure.<sup>1</sup>



*Figure 1: Perform color mapping of teeth while they are well-hydrated to determine depth of color for replacing dentin and the filtering effects of enamel.*



*Figure 2: Preoperative view of a typodont model. In a clinical scenario, a diagnostic mock-up would be analyzed to plan the case.*

The build-up or layering technique itself is one reflective of ceramist's principles. These use materials to interplay with light and recreate the hues, chromas, and values of color inherent to the tooth structure being replaced.<sup>2</sup> The direct composite build-up steps represent a process for completing a layered restoration similar to one fabricated with ceramic to replace dentin, enamel, dentin lobes, and characteristic colors. Mastery of these techniques forms the basic foundation for creating lifelike restorations, the quality of which is limited only by the imagination.

Imagination is key to the process and the manner in which a clinician's eye is trained to "see and observe" the natural tooth and match it in composite resin. This involves paying close attention to incisal effects (e.g., a halo), scalloping of the edges, heights of contour, surface texture, and light reflecting and deflecting zones. However, imagining what is possible requires an understanding of how natural tooth structure and its components—dentin and enamel and adjacent teeth themselves—interact with each other to create visual effects.<sup>3</sup>

For example, dentin has high points and low points to help light reflect differently. In natural teeth, there will be areas where a translucent layer will be thicker, so the dentin is deeper into the tooth. There will also be other areas where the translucent layer will be thinner, so the dentin will be closer to the surface of the tooth. The latter area is usually at the gingival half. Therefore, clinicians layering direct composite resin will want to ensure that they reestablish that dentin area using a dentin composite, being sure to bring it closer to the surface to create a lifelike restoration. Using too much translucent composite to "fill in" what was removed during preparation could result in a restoration that appears too low in value, too translucent, and not lifelike.

Also, consider that the teeth themselves demonstrate specific characteristics. Central incisors will have much more elaborate incisal characteristics and exhibit much more detail in terms of dentinal lobes. Any "blue" appearing in the central incisors might be stronger, whereas in the lateral incisors, it might appear more subtle or softer. The canines, on the other hand, will

demonstrate higher chroma and stronger color when compared from the laterals to the central. In terms of shape, by observing the axial inclinations of teeth, emergence profiles, and line angles, clinicians can realize the ways in which teeth differ among themselves.

Accreditation Case Type V tests the candidate's ability to create excellence with direct resin in minimally invasive ways<sup>4</sup> and comprehend smile design principles, as well as knowledge of tooth morphology.<sup>5</sup> Smile design principles include those related to lip line and midline placement; axial inclination and incisal embrasures of the teeth; principles of proportion and central dominance; the buccal corridor; and the contour, shape, and position of the gingival tissue.<sup>6,7</sup>

### KNOW THE ANTICIPATED OUTCOME OF THE CASE

Key to successful esthetic outcomes in esthetic restorative dentistry is envisioning the restorations prior to initiating treatment. Therefore, esthetically enhanced study models and wax-ups,<sup>8</sup> and a very solid shade diagram for each tooth showing how the shades vary within

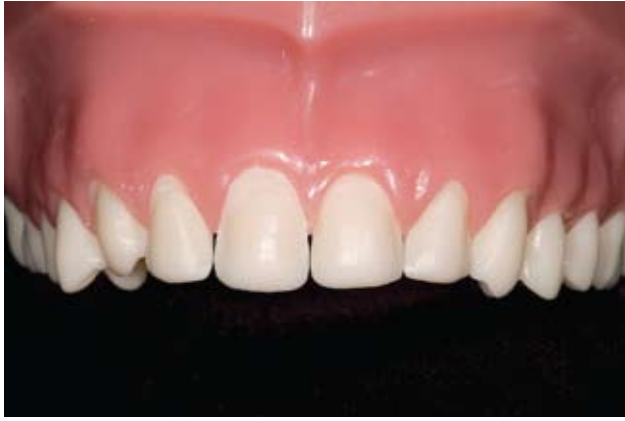

Figure 3: Facial view of teeth #6-11, demonstrating an aggressive preparation on a typodont.

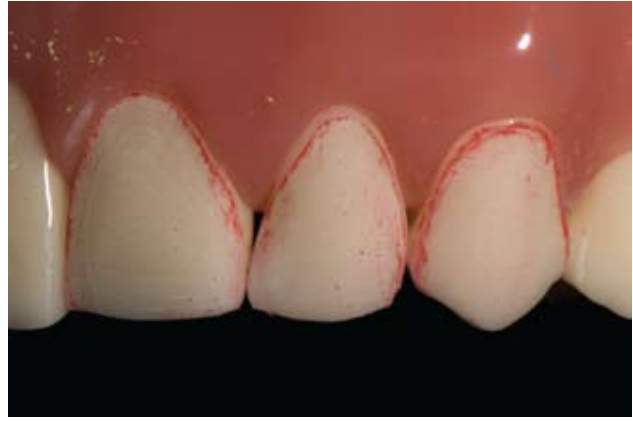


Figure 4: When minimal color change or contour change is needed, a less invasive or aggressive preparation is appropriate for Case Type V restorations.

the tooth itself (Fig 1), should be developed. Essentially, the restoration first must be created in the mind before it can be created in the patient's mouth. Diagnostic study models (Fig 2) and mock-ups facilitate understanding of how much material will be needed and how much enhancement or augmentation to the tooth structure will be required. Their use also enables clinicians to understand the contours of the teeth.

### CREATE MATRICES AND REDUCTION GUIDES

Preparation is of paramount importance when creating direct resin restorations. Too often, aggressive preparations are seen for composite veneers that could otherwise be completed with only slight removal of tooth structure or a conservative form of enamelplasty (Fig 3). It is discouraging to see too much tooth structure sacrificed unnecessarily for the sake of esthetics, especially when more conservative preparations can be completed with the use of a reduction guide (Fig 4). Polyvinyl siloxane (PVS) matrices will demonstrate the placement limits in terms of volume of composite ma-

terial three-dimensionally.<sup>9</sup> These can be used as adjuncts to help clinicians maintain the proper incisal length and edge thickness, as well as control midlines, as in cases involving diastemas and complex bonding (Figs 5-7).

---

*Imagining what is possible requires an understanding of how natural tooth structure and its components... interact with each other to create visual effects.*

---

### UNDERSTAND WHAT PART OF THE TOOTH IS MISSING FOR MATERIAL SELECTION

Performing color analysis of the tooth/teeth—commonly known as shade mapping—can help in material selection and placement.<sup>10</sup> Shade mapping is, quite simply, a drawing of the tooth that indicates specific shade names in the zones of the tooth where they are observed. To confirm that the shade mapping is correct, small increments of composite should be placed preoperatively on the teeth and light-cured. This will allow both the clinician and the patient to actually envision

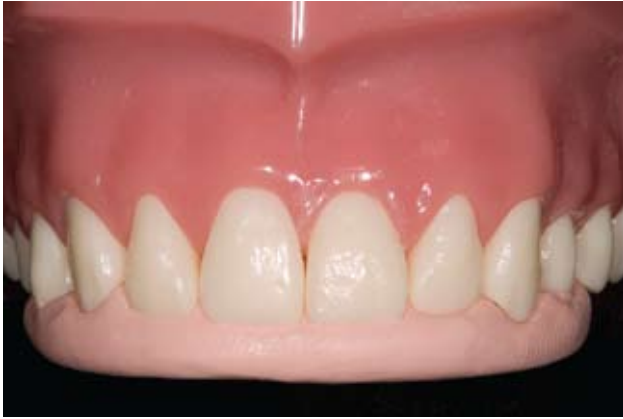and observe the material and determine if it is the right choice, as opposed to preparing the tooth, applying the material, and not knowing whether that is the right color.

### HANDLE THE COMPOSITE PROPERLY

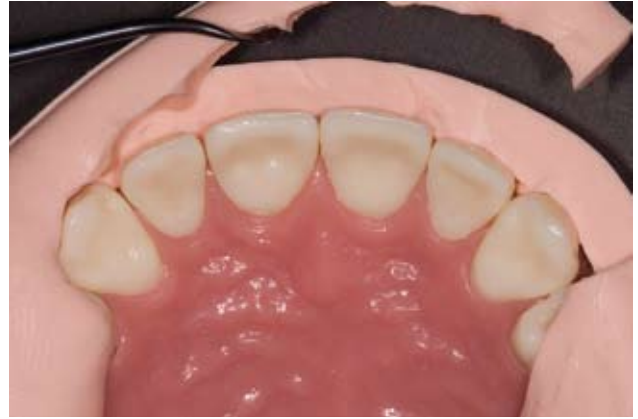The manner in which composite materials are handled—whether it is on the facial surface, interproximally, or around the gingival tissues—affects the appearance of the restorations. In order to handle the materials properly, it is important not to incorporate air voids into the composite increments that are being placed. Additionally, placing smaller increments predictably versus trying to control too much material at one time helps to ensure control of the material.

### USE A COMPOSITE LAYERING TECHNIQUE TO BUILD IN POLYCHROMICITY

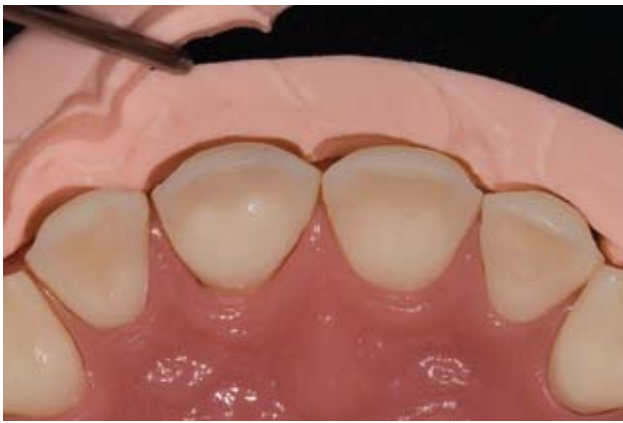For Case Type V, begin with the central incisors (teeth #8 and #9). Place an initial dentin replacement layer of the highest chroma shaded composite for that tooth (e.g., Vita-lescence cervical shade A1, Ultra-



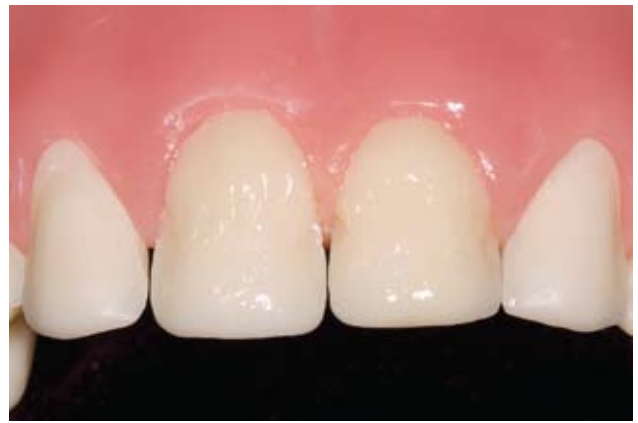*Figure 5: A PVS matrix must include the facial-incisal line angle to aid in the fabrication of the designed incisal edge plane and contour.*



*Figure 6: Incisal view of the reduction guide that will be used to confirm appropriate and uniform reduction and appropriate and harmonious contours in the final restorations.*



*Figure 7: Close-up view of the reduction matrix after preparation confirms that the desired reduction was achieved.*



*Figure 8: The initial dentin replacement layer (shade A1) was placed in the gingival half of the central incisors and extended partially into the incisal half.*

dent Products; South Jordan, UT) in the gingival half of the tooth, almost to full contour. Extend this composite layer partially into the incisal half and light-cure as directed by the manufacturer (Fig 8).

Then place a second layer of dentin replacement composite—now a body shade (e.g., Vitaescence body shade B1)—in the middle half of the tooth and extend this layer into the incisal third to start the development of the dentinal lobes. Be sure that there is still sufficient room on the facial aspect for the application of the enamel layer and then light-cure this increment (Fig 9).

To recreate the remaining lingual contour and incisal plane of the central incisors, apply an opaque (e.g., Vitaescence Opaque Snow) composite, using the matrix as a guide (Fig 10). Be careful not to fill between the dentinal lobe development, and ensure that sufficient room remains for application of the enamel layer.

---

*Performing color analysis of the tooth/teeth...can help in material selection and placement*

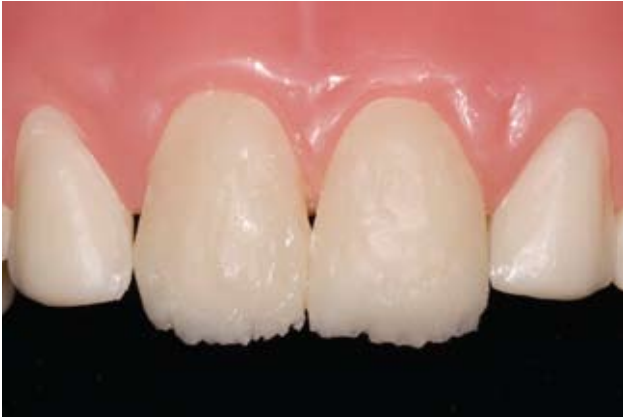---

### IMPART INCISAL EFFECTS

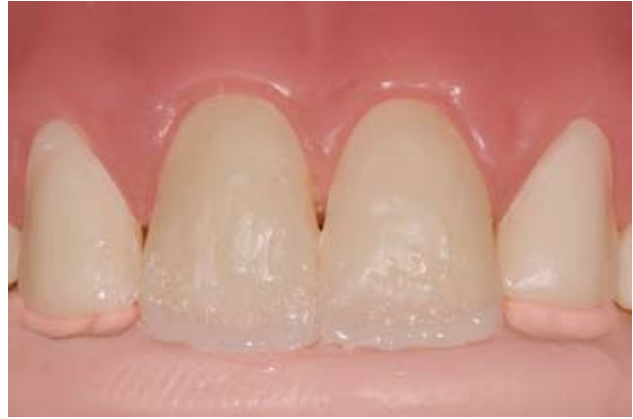Two different techniques can be employed to create incisal effects. The first technique (demonstrated on tooth #8) uses inherently tinted/colored composites (e.g., Vitaescence Iridescent Blue). The second technique (demonstrated on tooth #9) requires the use of tints (e.g., Vital color tints, Ultradent) and a mixture of unfilled resin. Reviewers have commented that an ability to use various tints, opaquers, and translucent enamel shades contributes to the convincing use of composite resin for AACD Case Type V restorations.<sup>11</sup>



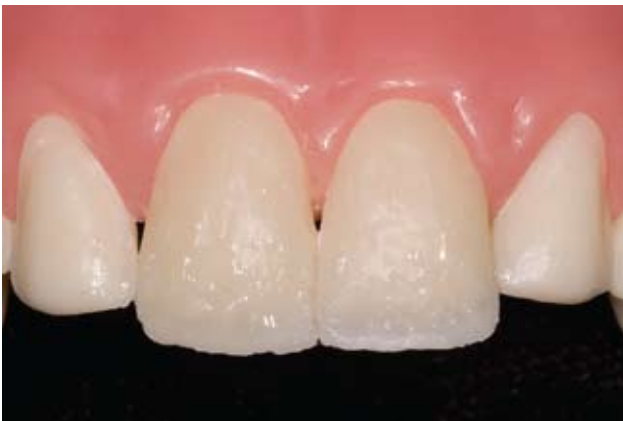LESAGE/MILNAR/WOHLBERG



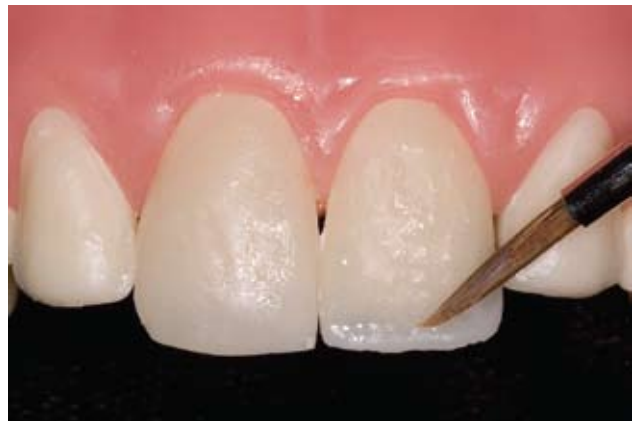*Figure 9: A second dentin replacement layer in shade B1 was placed in the middle half of the central incisors and extended to begin dentinal lobe development.*



*Figure 10: The remaining lingual contour and incisal plane was recreated by applying Opaque Snow composite, with the matrix as a guide.*



*Figure 11: Iridescent Blue composite was applied to tooth #8 primarily between the previously formed dentinal lobes to create incisal translucency.*



*Figure 12: A mixture of Vital blue 30% and 70% clear tints was applied to the incisal zone to establish the appropriate incisal translucency.*

#### TINTED COMPOSITE TECHNIQUE

Apply the tinted composite (Iridescent Blue) primarily between the dentinal lobes that were previously formed. This will create incisal translucency (Fig 11). Light-cure as directed. Be sure not to fill the lobes completely.

#### MIXTURE TECHNIQUE

Mix 30% blue tint (Vital blue) and 70% clear unfilled resin and apply the mixture to the incisal areas—including the transition zones on the mesial and distal aspects—

to establish the appropriate incisal translucency (Fig 12), as noted in the color mapping. Light-cure as directed.

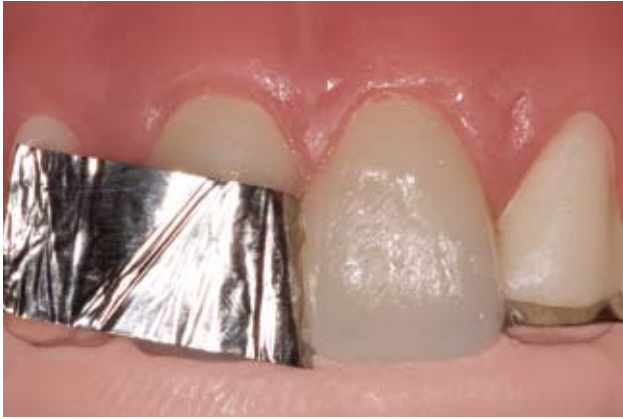Once the appropriate incisal effects have been created, complete the restorations of the central incisors by replacing the enamel layer with a final enamel shade of composite (e.g., Vitaescence Pearl Frost) (Fig 13). This enamel layer will provide a translucent effect and properly disperse light. Light-cure as directed.

#### ENSURE ISOLATION

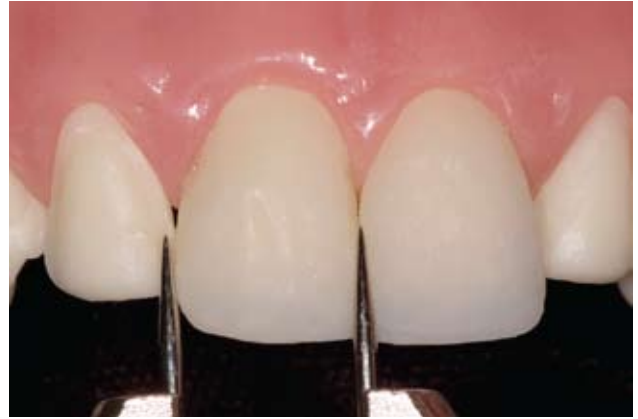Ensure proper isolation among the teeth to be restored and from oral fluids using rubber dam isolation, a dead soft matrix, or plumber Teflon tape. A sectional matrix may also be employed.

#### ASSESS

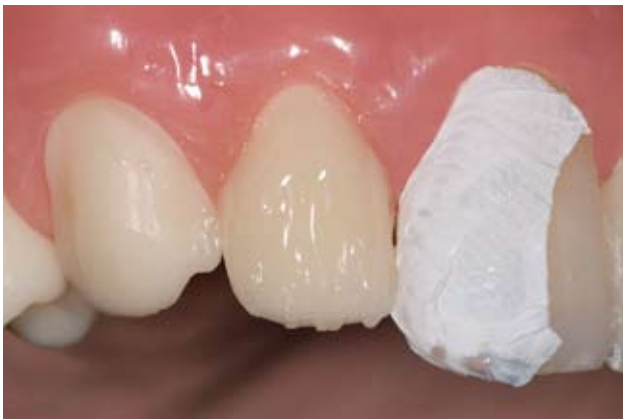When developing direct composite resin restorations for AACD Accreditation Case Type V, it is imperative that the restorations be assessed in progress. It is recommended that the central incisors be developed



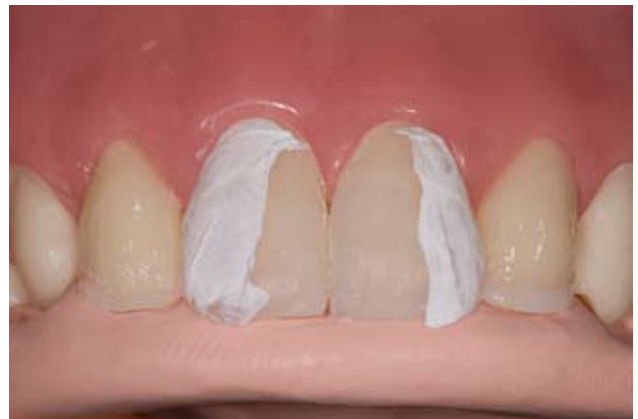*Figure 13: A final enamel layer in composite shade Pearl Frost was applied. Proper isolation with a dead soft matrix facilitates this process.*



*Figure 14: Calipers were used to measure the widths of the newly fabricated restorations in three areas—gingival, middle, and incisal—to ensure harmony and balance.*



*Figure 15: The initial dentin replacement layer (cervical/body A1 composite) was applied to teeth #7 and #10 in the gingival half almost to full contour.*



*Figure 16: The remaining lingual contour and incisal plane of teeth #7 and #10 was recreated by applying Opaque Snow composite.*

first, followed by the lateral incisors, then the canines. That being said, when the central incisors have been developed to approximately 80% to 90% of full contour, they should be assessed in terms of width and length symmetry, line angles, and harmonious balance (Fig 14). Calipers can facilitate this process. Once harmony and balance are confirmed, the restorative layering process can proceed to the lateral incisors (Figs 15-19). Similarly, when those restorations have reached approximately 80% to 90% of their full contour, they too should be assessed (Fig 20). Finally, the cuspids can

then be restored with a layering technique (Figs 21-26) and, upon reaching 80% to 90% of full contour, they too can be assessed (Fig 27).

### CONFIRM GROSS CONTOURS

Once the restorations have been successfully layered and anatomically constructed, clinicians should ensure that they have achieved a similar harmony and balanced width and length across the centrals, as well as balance with the laterals and cuspids. Using the flap door facial matrix, the clinician can confirm

that the restorations have the initial designed facial contour (Fig 28).

### IMPART TEXTURE AND REFINE ANATOMY

After the overall gross contours of the restorations have been confirmed, clinicians must ensure their realism by imparting texture and fine-tuning the tertiary anatomy. Note that using the matrix and carefully applying the composite helps to ensure accurate and precise placement, thereby simplifying the finishing process.<sup>12</sup> It is at this stage that the line angles should be-

LESAGE/MILNAR/WOHLBERG

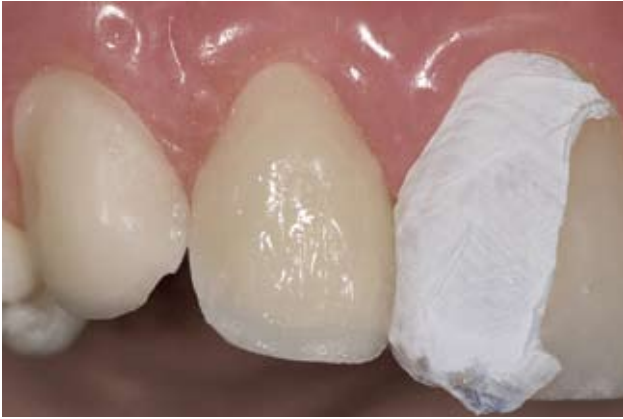

Figure 17: Iridescent Blue composite was applied to tooth #7 to create incisal translucency.

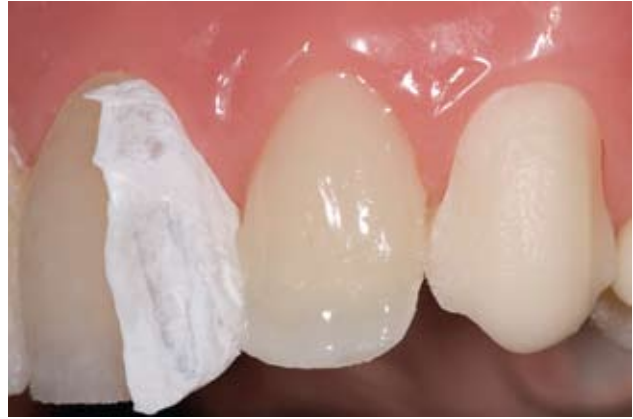

Figure 18: A mixture of Vital blue 30% and 70% clear tints was applied to the incisal zone of tooth #10.

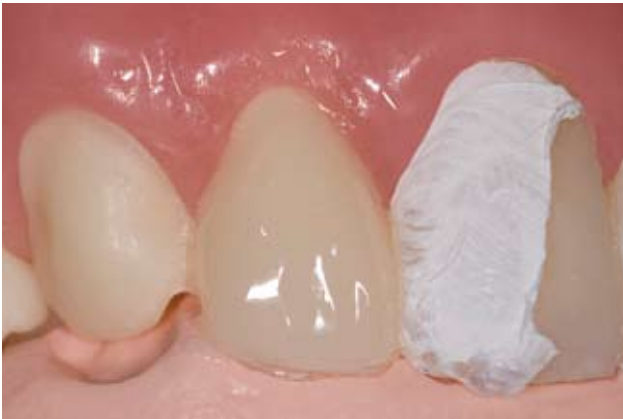

Figure 19: The final enamel layer of teeth #7 and #10 was applied in composite shade Pearl Frost.

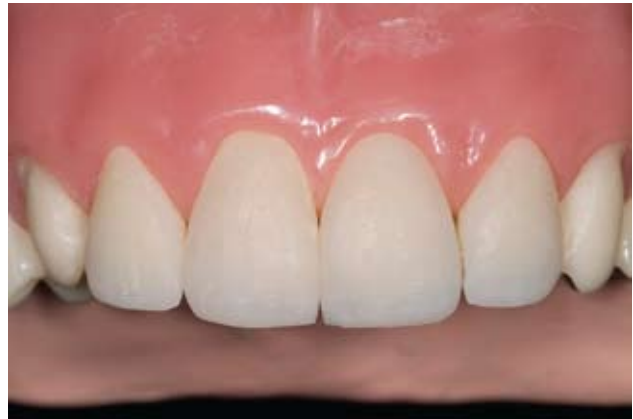

Figure 20: The widths of the newly fabricated restorations were assessed in three areas—gingival, middle, and incisal—to ensure harmony and balance.

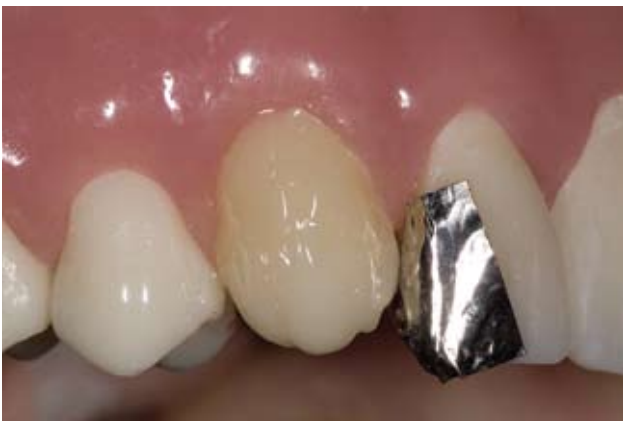

Figure 21: The initial dentin replacement layer (cervical shade A2) was placed in the gingival half of teeth #6 and #11 and extended partially into the incisal half.

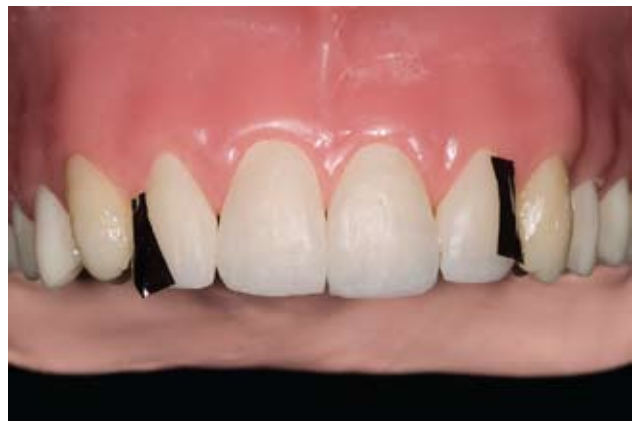
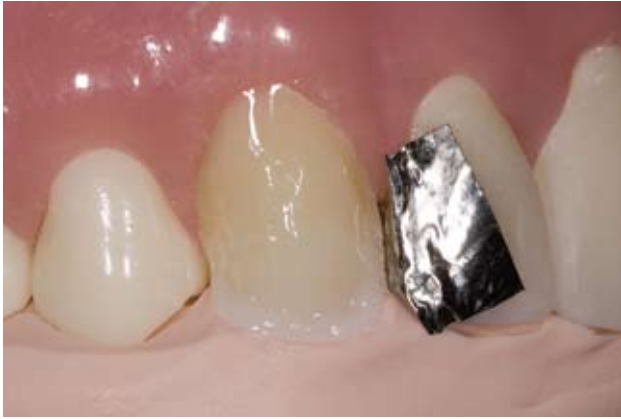
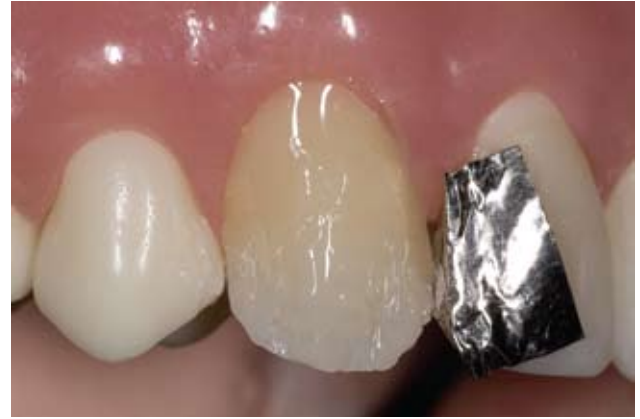Figure 22: A second dentin replacement layer (body shade A1) was placed in the middle half of teeth #6 and #11 and extended to begin dentinal lobe development.

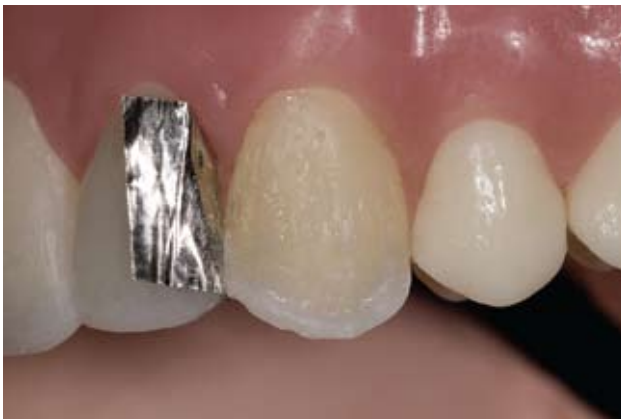



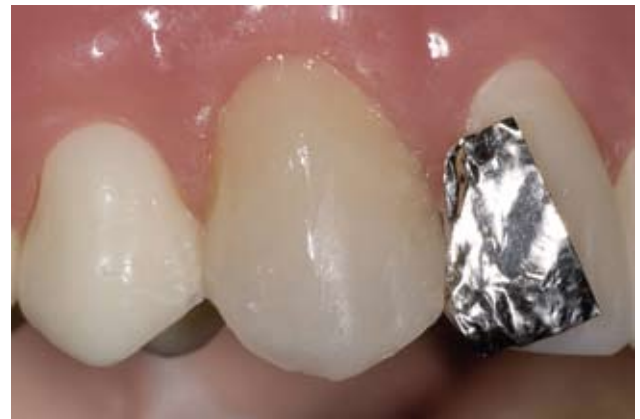*Figure 23: The remaining lingual contour and incisal plane was recreated by applying Incisal Edge Opaque Snow composite to teeth #6 and #11.*



*Figure 24: Cuspids tend to have less incisal translucency effect. On tooth #6, Iridescent Blue composite was applied to create incisal translucency.*



*Figure 25: On tooth #11, a mixture of Vital blue 30% and 70% clear tints was applied to the incisal zone to create incisal translucency.*



*Figure 26: The final enamel layer of teeth #6 and #11 was created by applying Final Enamel Shade Pearl Neutral composite.*

come more well-defined (e.g., secondary anatomy, tertiary anatomy) (Figs 29 & 30). To this end, it is important for clinicians to have a logical, sequential, and predictable method of finishing and polishing (e.g., UCLA LeSage Anterior Aesthetic Restorative System, Brasseler USA [Savannah, GA]; Jiffy [Ultradent]) that ultimately leads to a restoration surface that is ready to accept and reflect light, not one full of voids and defects, stains and pits. For example, a green striped diamond (#6856L-020) in a slow-speed, air-driven handpiece (NSK, Brasseler) can be

used to incorporate secondary and tertiary anatomy.

### **POLISH; VERIFY OCCLUSION**

To achieve the appropriate luster and polish, a good polishing system that includes polishing paste, points, cups and wheels (e.g., Jiffy) is recommended for esthetic direct composite restorations (Figs 31 & 32). The final luster and polish can be obtained using a goat hair chamois brush (Brasseler) or a regular chamois brush with polishing paste, starting wet and then dry (Fig 33). When the restorations have

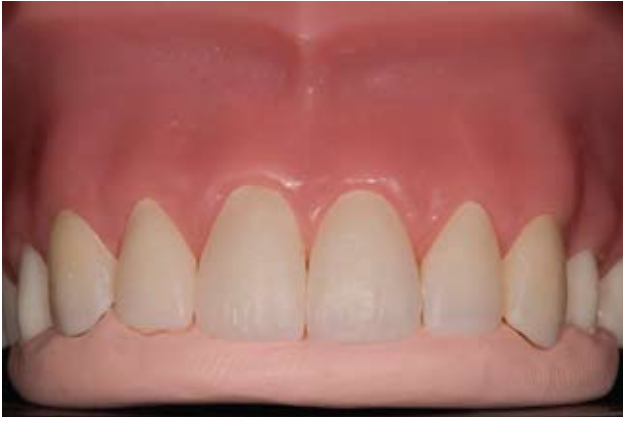been finished and polished, the occlusion should be verified.

### **CONCLUSION**

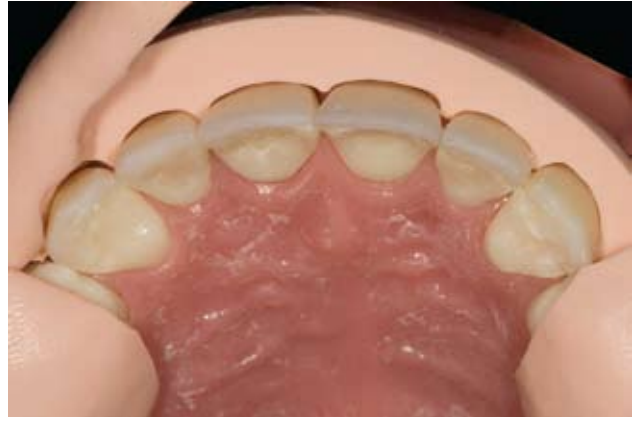As clinicians prepare to elevate their skills in providing their patients with direct composite restorations, it is important for them to know the principles of nature and to correlate them with their restorative materials. What is required for esthetic and functional excellence during this time of minimally invasive dentistry is an evolution of skills based on an understanding of what polychromicity is; the different thicknesses of



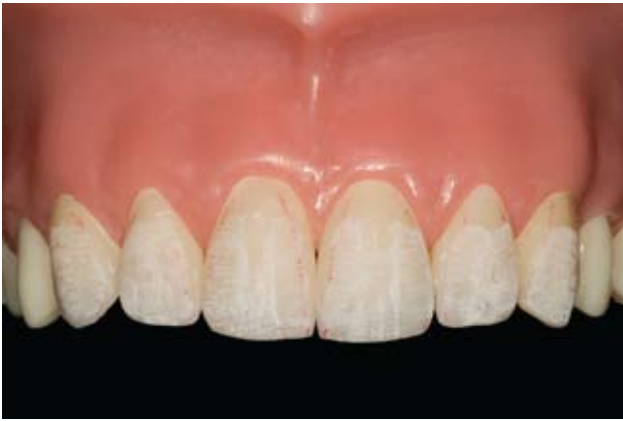LE SAGE/MILNAR/WOHLBERG



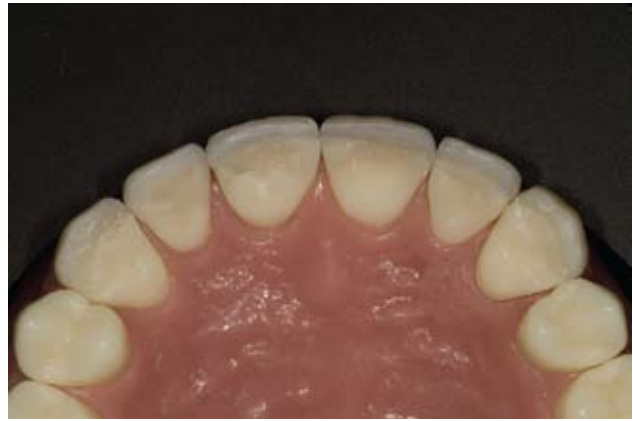**Figure 27:** Since the PVS matrix was used for development of the incisal edges, note that a true fit was confirmed during assessment of the restorations.



**Figure 28:** Incisal view of the polyvinyl siloxane matrix. Note the proximity of the matrix and the facial contour of the final restorations in the gingival half.



**Figure 29:** Faint red lines scribed on the composite outline the transition line angles. Texture can be carried to and beyond the line angles to simulate nature.



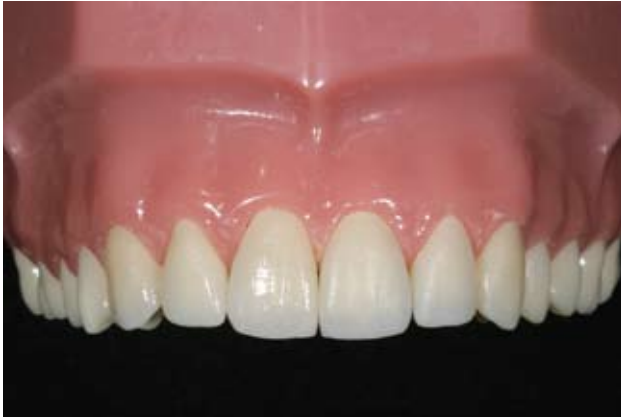**Figure 30:** Incisal view of the final restorations. Clinicians should see well-demarcated line angles and a similar amount of facial surfaces and anatomy on contralateral restorations.

dentin and enamel in different parts of the tooth; and how to vary the hue, chroma, and value of the composite restorations that are systematically layered. The keys to success are observation and strategic control, and careful selection and manipulation of the desired composite material. Additionally, on an AACD Accreditation Case Type V, it is essential to use a comprehensive restorative system that provides all the requisite shade opacities, translucencies, and dentin and enamel colors and tints (e.g., Vitalescence; Premise, Kerr [Orange, CA]; 4 Seasons, Ivo-

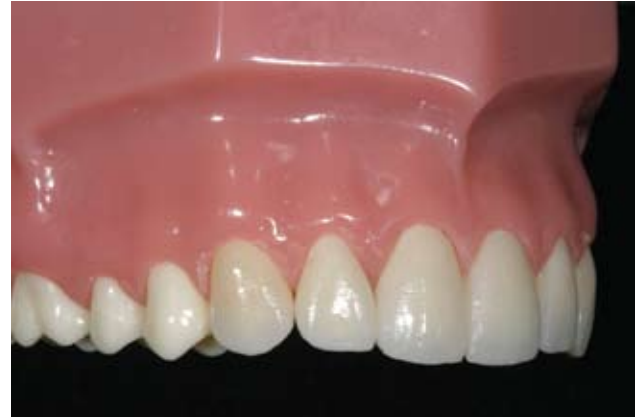clar Vivadent [Amherst, NY]; Filtek Supreme, 3M ESPE [St. Paul, MN]; Esthet•X, Dentsply Caulk, [Milford, DE]).<sup>13</sup> Having an array of composite shades and opacities is ideal when developing Case Type V.

#### References

- Blank JT. Simplified techniques for the placement of stratified polychromatic anterior and posterior direct composite restorations. *Compend Contin Educ Dent* 24(2 Suppl):19-25, 2003.
- Jackson RD. Understanding the characteristics of naturally shaded composite resins. *Pract Proced Aesthet Dent* 15(8):577-85, 2003.
- Terry DA, Geller W, Tric O, Anderson MJ, Tourville M, Kabashigawa A. Anatomical form defines color: Function, form, and aesthetics. *Pract Proced Aesthet Dent* 14:59-67, 2002.
- White JM, Eakle WS. Rationale and treatment approach in minimally invasive dentistry. *JADA* 131 June(Suppl:13S-19S), 2002.
- Bakeman B. Introduction to Accreditation essentials. *Journal of Cosmetic Dentistry* 23(3):20-21, 2007.
- Blitz N, Steel C, Willhite C. *Diagnosis and Treatment Evaluation in Cosmetic Dentistry: A Guide to Accreditation Criteria*. Madison, WI: American Academy of Cosmetic Dentistry; 2001.
- De Castro MV, Santos NC, Ricardo LH. Assessment of the "golden proportion"



**Figure 31:** Using rubber points, cups and wheels, a disc system, and a silicone impregnated brush, clinicians can attain a luster and polish appropriate for individual cases.



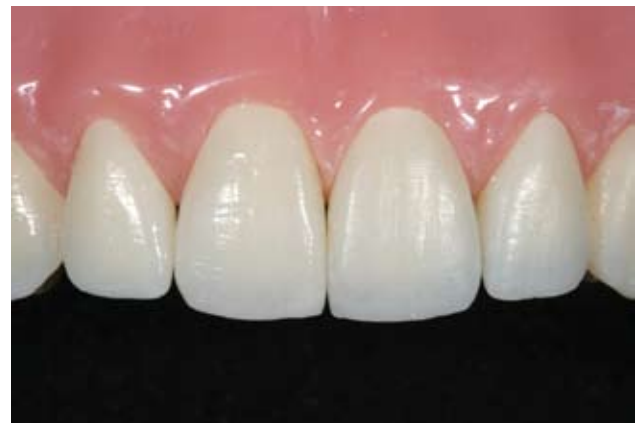**Figure 32:** Note the gradation of color using the parameters of value and chroma moving from the central to the lateral to the cuspid.

- in agreeable smiles. *Quintessence Int* 37(8):597-604, 2006.
8. Small BW. Pretreatment wax-ups and provisionals for restorative dentistry. *Gen Dent* 53(2):98-100, 2005.
  9. Behle C. Placement of direct composite veneers utilizing a silicone build-up guide and intraoral mock-up. *Pract Perio Aesthet Dent* 12(3):259-266, 2000.
  10. Terry DA, Leinfelder KF. An integration of composite resin with natural tooth structure: The Class IV restoration. *Pract Proced Aesthet Dent* 16(3):235-42, 2004.
  11. Arnold JF III. Examiners' perspective for Emil Hawary (Accreditation Essentials). *Journal of Cosmetic Dentistry* 23(3):29, 2007.
  12. Peyton JH. Finishing and polishing techniques: Direct composite resin restorations. *Pract Proced Aesthet Dent* 16(4):293-298, 2004.
  13. Milnar FJ. Altering tooth inclination and overall esthetics with direct composite veneers, gingival contouring, and enamelplasty. *Inside Dent* 2(1):46-49, 2006.

#### AACD Acknowledgments

The American Academy of Cosmetic Dentistry recognizes Dr. Brian LeSage as an AACD Accredited Fellow and a Give Back A Smile<sup>®</sup> (GBAS) volunteer, Dr. Frank Milner as an AACD Accredited Member, and Jenifer Wohlberg as an AACD Accredited Member who has donated many laboratory cases to restore the smiles of GBAS survivors.

*AL*



**Figure 33:** Use goat hair brushes and chamois wheels with wet and dry composite polishing paste; as seen on the right side of the tyodont, a high polish is attainable.

