

AESTHETIC SOFT TISSUE MANAGEMENT: Predictable Care Using Contemporary Techniques and Applications

Anthony G. Gallegos, DDS* • Michael J. Koczarski, DDS† • Ernesto A. Lee, DMD‡ • Brian P. LeSage, DDS§

The concomitant evolution of predictable tissue-contouring techniques and innovative dental materials has significantly improved the aesthetic potential of prosthetic restorations. Proper tissue management allows the development of pontic sites and natural emergence profiles. Gingival contours must be maintained, and a stable soft tissue environment that will ensure predictable rebound of the gingival margin following retraction and impression-taking procedures must be created (Figures 1 through 3). In that regard,

"Healthy tissues can be maintained when margins are placed supra-gingivally, at the crest, or just below the crest, where they can be maintained by the patient."

— Anthony G. Gallegos, DDS

it is of utmost importance to establish adequate gingival health. The presence of excessive gingival inflammation introduces an additional variable that may negatively affect the stability of the gingival margin and result in recession and exposed margins in the final restoration.

HEMOSTASIS

Critical to the preservation of viable soft tissue architecture is the use of hemostatic agents that enable the clinician to maintain a stable environment during the retraction, impression, and provisionalization stages. The application of aluminum chloride (eg, Hemodent, Premier, Norristown, PA), ferric sulfate (eg, ViscoStat Plus and Astringident, Ultradent Products, South Jordan, UT), or epinephrine hemostatic agents prior to tissue retraction enables control of sulcular hemorrhage to prevent bleeding during the manipulation of gingival tissues. Once the selected hemostatic agent is applied, care must be taken to remove excess material from the retraction cord to decrease the potential for soft tissue damage.

TISSUE RETRACTION

While many crown and veneer restorations may utilize supragingival margins that do not necessitate retraction techniques, margins placed beneath the soft tissues require the use of traditional cord retraction (eg, Ultrapak, Ultradent, South Jordan, UT) or a cord replacement material (eg, Expa-syl, Kerr/Sybron, Orange, CA) to ensure protection of the gingival tissues. Excessive pressure during the cord packing

procedure may result in biologic width impingement that may ultimately lead to recession. Since the retraction material absorbs the oral fluids as it expands, pressure is exerted on the surrounding tissues to effect gingival displacement.

"Tissue management is essential to ensure that the definitive restorations are well-seated, well-fitted, do not leak, and are well-contoured."

— Brian P. LeSage, DDS

Although most cord retraction techniques incorporate the use of a hemostatic agent, it is the method of application rather than the choice of solution that may influence the predictability of gingival margin levels. The retraction device should be allowed to remain in contact with the gingival sulcus for a minimum of 5 minutes prior to impression taking to ensure proper tissue displacement, regardless if the margin is placed at the crest of the gingiva or subgingivally. A double-cord technique can be used prior to preparation, and the ends of the cords should not interlap (Figures 4 and 5). Once the preparation is completed down to the cord level, this cord is

removed during impression making to enable accurate capture of the finish line. (Figure 6).

PONTIC SITE DEVELOPMENT

An ovate pontic form is indicated for the treatment of partial edentulism when soft tissue aesthetics are of paramount importance (Figure 7). Pre-operative evaluation must include radiographic evaluation of the site that is going to be altered, bone sounding to determine the level of bone present, and a diagnostic model to ensure development of a natural emergence profile (Figure 8). Use of a diagnostic waxup also allows the clinician to preview the aesthetic result before the patient's tissue is ever touched with a bur, surgical instrument, or laser.

An ovate pontic has an ovoid (or egg-shaped) tissue surface that is convex in faciolingual and mesiolingual directions. The ovoid tissue surface must be recessed into a socket that is prepared in the crest of the ridge in order for the pontic to appear natural. The rounded base of the pontic must be accurately formed to precisely fill the prepared concave recipient site. Sockets are created using surgical diamonds or

proceed to page 15

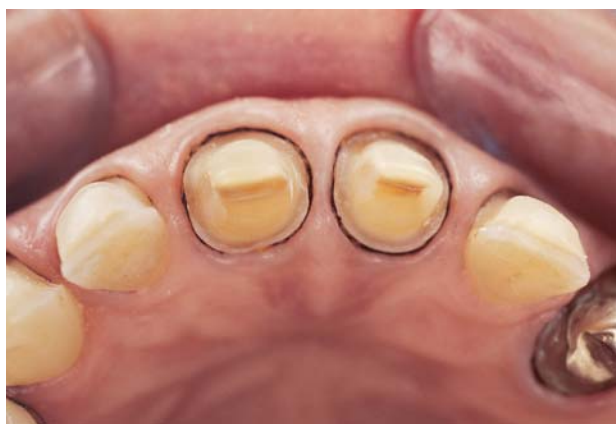

FIGURE 1. Adequate subgingival tissue retraction is essential to the preservation of the soft tissue architecture during impression taking.

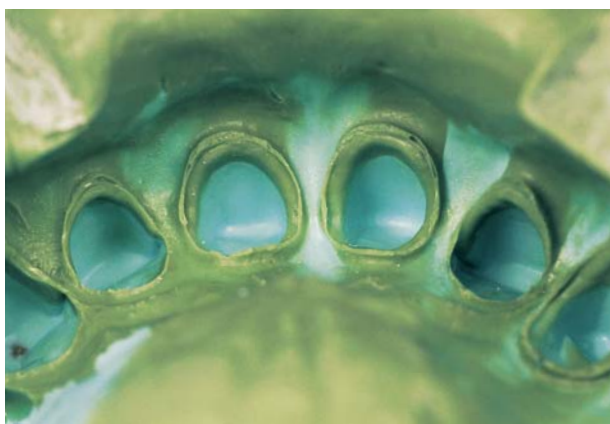


FIGURE 2. Transfer of critical hard and soft tissue contours is possible when the hard and soft tissue architecture is accurately captured during the impression-taking procedure.

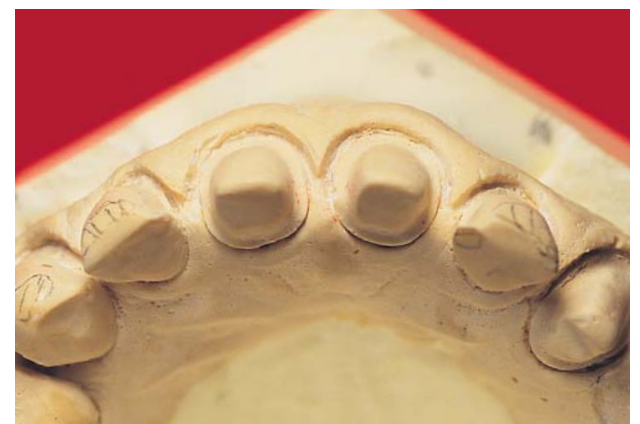


FIGURE 3. Once the impression is taken, a stone model is poured to further communicate the contours of the prepared dentition.

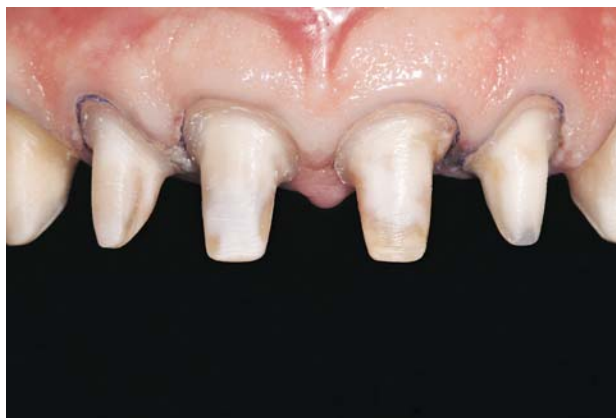

FIGURE 4. The initial retraction cord layer was atraumatically placed. Care was taken to maintain the gingival contour and avoid impingement of the attachment apparatus.

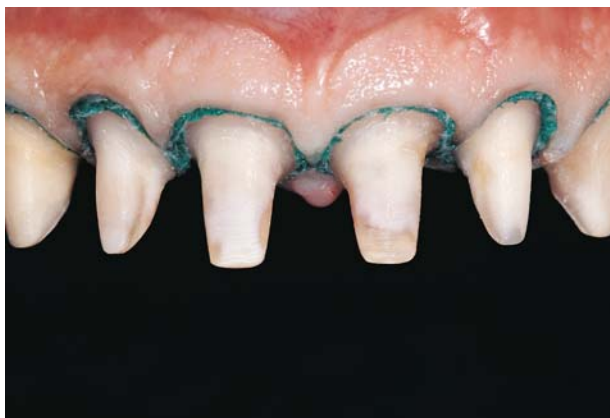

FIGURE 5. The second cord layer must be visible 360 degrees around the finish line for effective lateral tissue displacement.

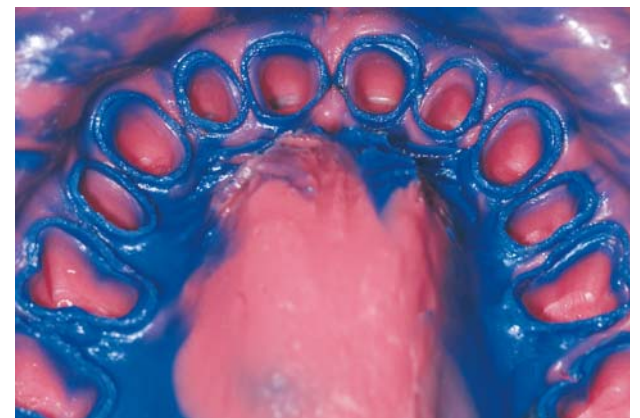

FIGURE 6. A definitive full-arch impression accurately captured hard and soft tissue architecture of the 12 consecutive abutments.

SOFT TISSUE MANAGEMENT

continued from page 13

electrosurgery (Figure 9). Once the socket is sculpted, acrylic is added to the tissue surface of the pontic to ensure the development of proper socket contour. Following 3 to 6 weeks of healing, ridge formation and tissue healing can be verified, provisionalization can be implemented, and the definitive restoration can be placed when sufficient architecture is confirmed (Figure 10).

A well-formed ovate pontic provides an aesthetic appearance that is virtually indistinguishable from a natural tooth, as well as patient comfort since food impaction is essentially eliminated. Due to their convex tissue surface, ovate pontics provide optimal access for oral hygiene and its broad shape can be easily cleaned with floss.

TISSUE MANAGEMENT USING LASERS

The development and application of pulsed (eg, Nd:YAG, American Dental Technologies, Southfield, MI) and diode (eg, Waterlase, Biolase, San Clemente, CA) lasers have resulted in significant advancements in soft tissue manipulation. In addition to their proven efficacy in soft tissue contouring, recent developments have resulted in the application of diode lasers for a variety of functions that include cavity preparation, caries removal, and tooth etching. Laser soft tissue management systems facilitate the elimination of

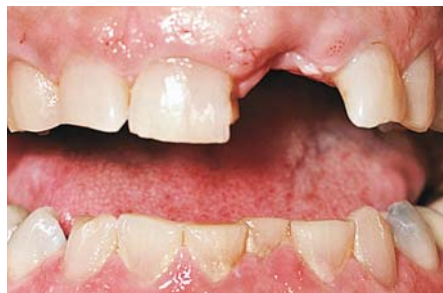

FIGURE 7. An ovate pontic form is indicated for the maintenance of aesthetic soft tissue harmony.

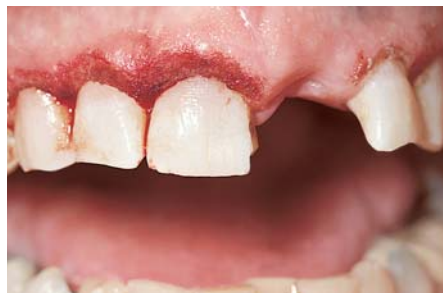

FIGURE 9. Laser gingivectomy was performed prior to provisionalization and hemostasis was maintained.

pain and bleeding while removing bacteria from damaged gingival tissues. While traditional laser systems have resulted in excess alteration of the gingival interface with unpredictable results, the increased application of contemporary laser devices allows the clinician to perform reliable, consistent soft tissue surgery for subsequent aesthetics and tissue integration.

PROVISIONALIZATION

The placement of provisional restorations enables maintenance of the

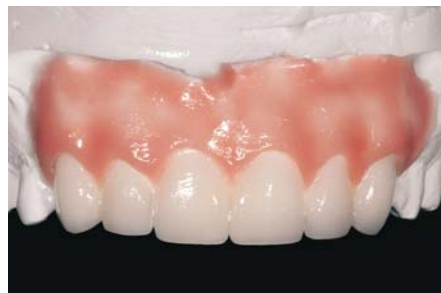

FIGURE 8. Diagnostic waxups can be used on mounted models for patient consultation and acceptance of the desired outcome.

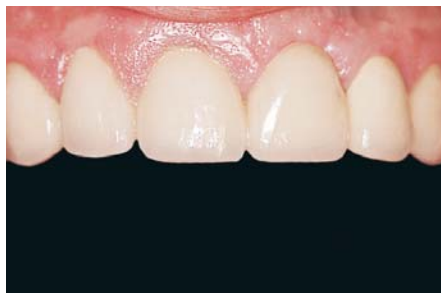

FIGURE 10. Once an appropriate healing and provisionalization period has been observed, the definitive restorations can be placed for an aesthetically enhanced tissue appearance and health.

tooth position and prevents shifting of the hard and soft tissues during laboratory fabrication of the definitive restorations. Provisional restorations function as a prototype to determine the accurate length, contours, relationship, midline, incisal edge anatomy, gradation of color, central dominance, embrasure forms, axial inclinations, surface anatomies, and textures. Patients are awarded the opportunity to communicate any desired modifications that may be necessary prior to delivery of the final restorations, and

impressions of directly fabricated provisionals (eg, LuxaTemp Automix, Zenith/DMG, Englewood, NJ; Jeltemp, HK Jelenko, Armonk, NY) can be used to effectively communicate patient approval to the laboratory technician. Tissue management during chairside fabrication of the provisional restorations can be facilitated by ensuring proper finishing to the prepared teeth using tissue retractors and diamond finishing burs. Provisional restorations can also be fabricated extraorally (eg, Biotemps, Glidewell Laboratories, Newport Beach, CA) following acquisition of an impression and quick-setting model (Figures 11 through 14). The laboratory technician can then use the information about the existing tissue contours and preparation designs as a template for fabrication of the provisional and definitive restorations.

CONCLUSION

Clear and exact margin duplication is paramount to the development of a precise impression and accurate-fitting restoration. The patient must be instructed on how to care for and maintain the tissue/restorative interface to

"The procurement of accurate elastomeric impressions represents a clinical challenge that requires the implementation of a thorough, comprehensive protocol."

— Ernesto A. Lee, DMD

ensure appropriate tissue management throughout the provisionalization stage and successful placement of the definitive restorations with minimal complications. Most patients are more acutely aware of their overall smile and thus more easily convinced of the necessity for periodic recalls and oral hygiene following aesthetic treatment. The use of contemporary tissue management techniques enables the clinician to provide predictable and painless care throughout the various stages of treatment to ensure an aesthetically pleasing and satisfactory result. ■

Acknowledgment

Figures 1 through 3 appear courtesy of Irfan Ahmad, BDS. Figures 4 through 6 appear courtesy of Ernesto A. Lee, DMD. Figures 7, 9, and 10 appear courtesy of Herbert I. Bader, DDS. Figures 8 and 11 through 14 appear courtesy of Brian P. LeSage, DDS.

*Private practice, Yorba Linda, California.

†Private practice, Woodinville, Washington.

‡Adjunct Clinical Professor, Advanced Program in Aesthetic Dentistry, New York University College of Dentistry, New York, New York; Assistant Clinical Professor, Postdoctoral Periodontal Prosthesis, University of Pennsylvania School of Dental Medicine, Philadelphia, Pennsylvania; private practice, Bryn Mawr, Pennsylvania.

§Director, UCLA Aesthetic Continuum, Levels I and III and Co-director Level II, UCLA School of Dentistry, Los Angeles, California; private practice, Beverly Hills, California.

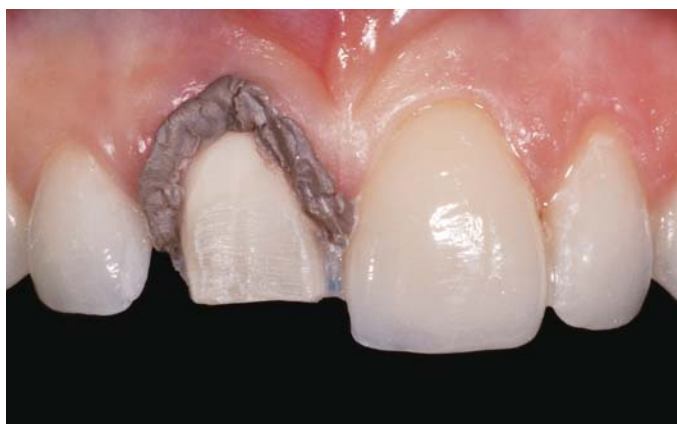

FIGURE 11. Preoperative view upon initial preparation of tooth #8(11). Tissue retraction was obtained using a cord replacement material (Expa-syl, Kerr/Sybron, Orange, CA).

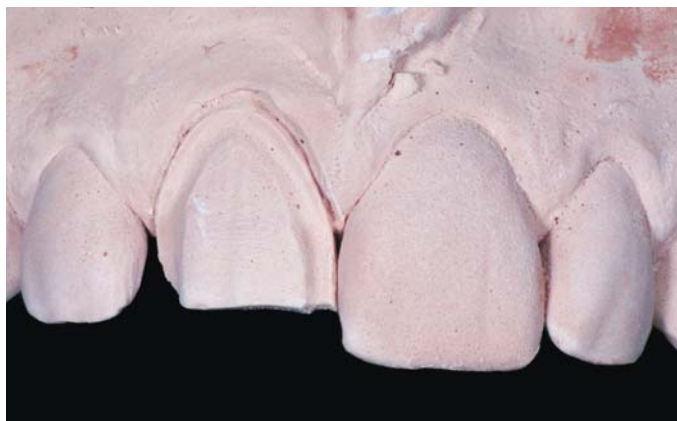

FIGURE 13. Based on the information obtained during the impression-making phase, precise models of the existing tissue architecture can be created. The die model of tooth #8 demonstrates a clear and readable chamfer margin.

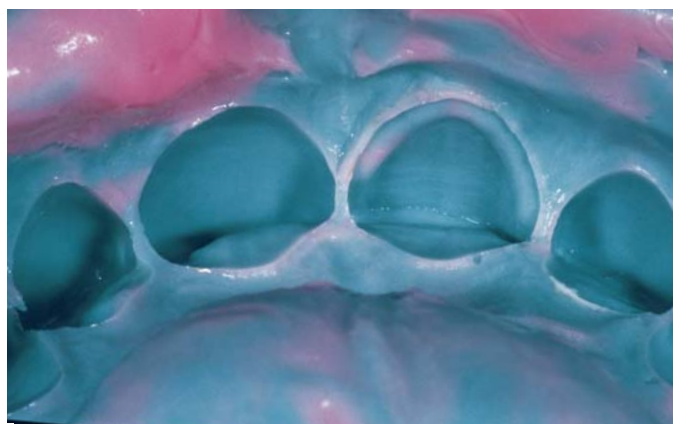

FIGURE 12. A reversible hydrocolloid impression was taken. Note the extension of impression material well beyond the defined margins.

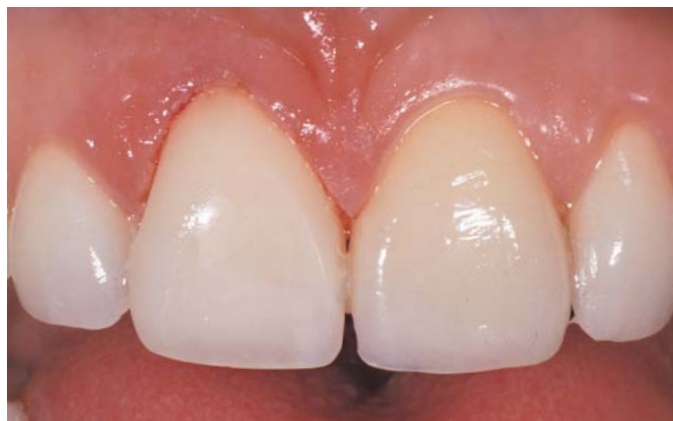

FIGURE 14. A bis-acrylic provisional restoration was fabricated and demonstrated precise contours and polish. Minimal tissue trauma was evident.